

Microtia Reconstruction: Our Strategies to Improve the Outcomes

Mohit Sharma¹ Srilekha Reddy G.² Shruti Kongara² Vasundhara Jain² Shravan Rai K.S.³
Ankita Harijee² Abhinandan Badam² Nirav G. Maharaja² Thomas Joseph⁴ Janarthanan R.²
Subramania Iyer²

¹Department of Plastic and Reconstructive Surgery, Amrita Hospital, Faridabad, Haryana, India

²Amrita Institute of Medical Sciences, Kochi, Kerala, India

³Tara Healthcare, Jayanagar, Bengaluru, Karnataka, India

⁴Department of Plastic and Reconstructive Surgery, KMC Hospital, Mangalore, Karnataka, India

Address for correspondence Mohit Sharma, MBBS, MS, MCh (Plastic and Reconstructive Surgery), Professor and Head of the Department of Plastic and Reconstructive Surgery, Amrita Hospital, Faridabad, Haryana 121002, India
(e-mail: ammasmohit@gmail.com; mohitsharma@fbd.amrita.edu).

Indian J Plast Surg

Abstract

Introduction: Autologous costal cartilage framework placement is currently the gold standard in patients with microtia. In this article, we present the modifications developed by the author, generally following the principles established by Nagata, and discuss the technical details that have led us to achieve consistently stable and good long-term outcomes for auricular reconstruction in microtia.

Materials and Methods: A retrospective review of microtia reconstruction performed from 2015 to 2021 was done. Those who underwent primary reconstruction for microtia and with a minimum follow-up of 6 months with documented photographs were included. Those who underwent secondary reconstruction for microtia and those who did not follow-up for a minimum period of 6 months were excluded. Outcomes were assessed with regard to appearance, and durability of the result. Influence of certain changes like delaying reconstruction until 15 years of age, use of nylon for framework fabrication, etc. over the outcome were assessed.

Results: Of 11 ears reconstructed at less than 15 years of age, only one patient (9%) had a good long-term outcome, whereas of the 17 ears reconstructed at greater than 15 years of age, nine patients (53%) had a good long-term outcome. In our experience, infections and wire extrusions were the significant events related to severe cartilage resorption.

Conclusion: In our experience, delaying the first stage to 15 years or later, using double-armed nylon sutures, and reducing the projection of the third layer of the framework in select cases have helped to improve our outcomes. Second stage of reconstruction can be avoided if patient is satisfied with the projection achieved in the first stage.

Keywords

- ▶ microtia reconstruction
- ▶ single-stage ear reconstruction
- ▶ ear framework fabrication
- ▶ wire extrusion
- ▶ improving outcomes of ear reconstruction

DOI <https://doi.org/10.1055/s-0043-1762907>.
ISSN 0970-0358.

© 2023. Association of Plastic Surgeons of India. All rights reserved.
This is an open access article published by Thieme under the terms of the Creative Commons Attribution-NonDerivative-NonCommercial-License, permitting copying and reproduction so long as the original work is given appropriate credit. Contents may not be used for commercial purposes, or adapted, remixed, transformed or built upon. (<https://creativecommons.org/licenses/by-nc-nd/4.0/>)
Thieme Medical and Scientific Publishers Pvt. Ltd., A-12, 2nd Floor, Sector 2, Noida-201301 UP, India

Introduction

The earliest description of ear reconstruction dates back to 600 BC, as *Karna Sandhan* in *Sushruta Samhita*.^{1,2} Since then, there have been significant advances in reconstructive techniques for auricular reconstruction starting with Gillies, who described placing carved maternal cartilage under the mastoid skin.³⁻⁵ Tanzer described the use of autologous costal cartilage⁶ and then Brent and Nagata laid the foundation for the techniques that are currently used.⁷⁻¹⁰ Autologous costal cartilage framework placement is currently the gold standard in patients with microtia.

The complexity involved in recreating the three-dimensional structure and achieving symmetry with the opposite ear, makes auricular reconstruction one of the most challenging surgeries for a plastic surgeon.

In this article, we present the modifications developed by the author, generally following the principles established by Nagata, and discuss the technical details that have led us to achieve consistently stable and good long-term outcomes for auricular reconstruction in microtia.

Materials and Methods

A retrospective review of microtia reconstruction performed from 2015 to 2021 was done. Those who underwent primary reconstruction for microtia and with a minimum follow-up of 6 months with documented photographs were included. Those who underwent secondary reconstruction for microtia were excluded.

The results were graded as: good, if the framework was appropriately positioned, critical components were distinctly

noted, and semblance of an ear was achieved; fair, if there was resorption of one or more of the individual components but semblance of a normally positioned ear was maintained; and poor, as one that has severe deformity or near complete resorption.

We follow Nagata classification for auricular deformities because of its direct clinical relevance in the surgical decision-making. The present established age of microtia reconstruction is around 8 to 10 years⁷⁻¹⁰ and the minimum chest circumference required for harvesting adequate costal cartilage is 60 cm at the xiphisternum.¹¹

In the hands of the author (MS), most of the long-term stable outcomes have been achieved between the ages of 15 and 25 years. One subjective clinical parameter is the resistance encountered during the lower rib cage compression when the patient is lying supine on a firm examination table. We have observed that the chests that are easily compressible provide cartilage that has smaller volume, is softer and weaker, and hence does not withstand the compressive and shearing forces of skin envelope well, over a period of time. We evaluate the dimensions and position of the uninvolved ear to create a template for the ear to be reconstructed, using auricular templates of standard sizes on transparent film. The template is used as a guide to create the framework of appropriate size and shape but no attempt is made to recreate the exact replica of the opposite ear.

First Stage: Costal Cartilage Framework Fabrication and Insertion into the Skin Pocket

Position of auricle and skin incision for pocket creation are marked (→ Fig. 1). Pocket creation and cartilage harvest are done simultaneously with two-team approach.

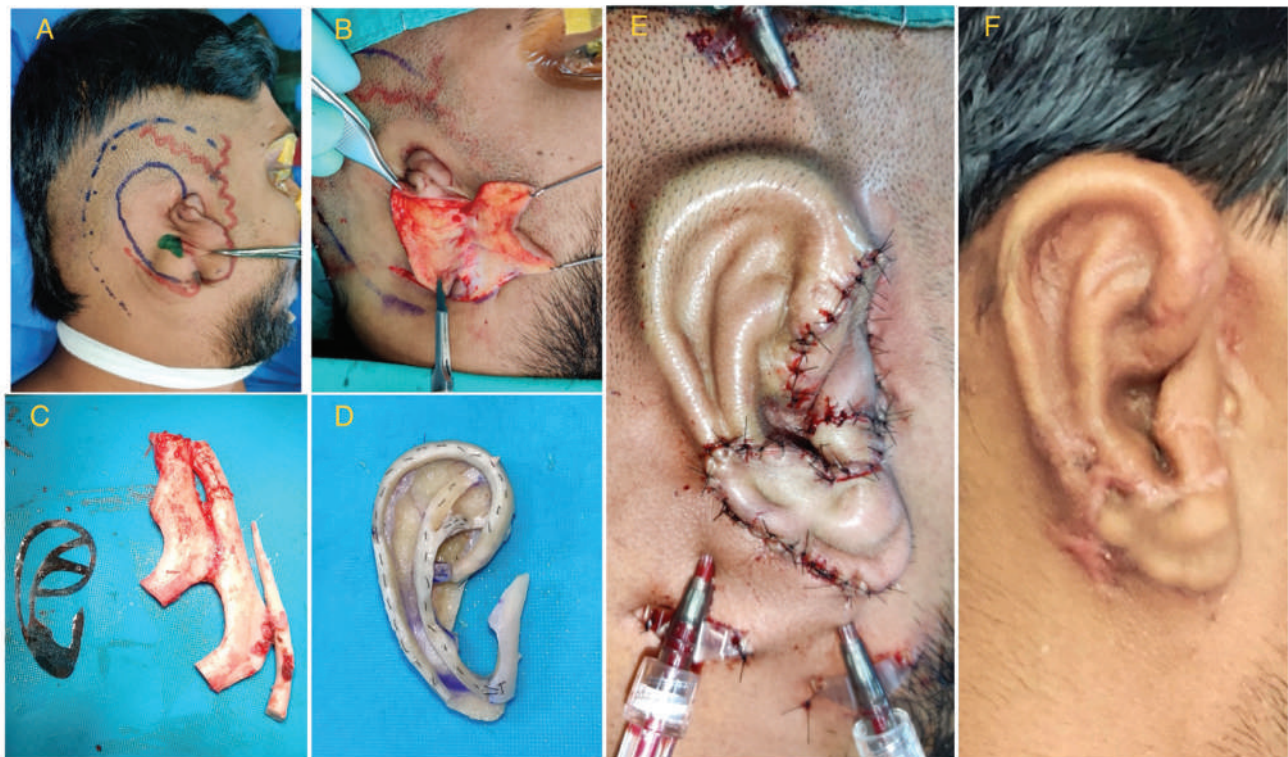

Fig. 1 First stage of microtia reconstruction: preoperative marking (A); split lobule with fine vessels preserved at base of flap (B); 6, 7, and 8 costal cartilages harvested (C); cartilage framework (D); immediate postoperative result—note suction drain system created using 16G cannulas (E); and final result 1.5 years later (F).

Three-layered ear framework fabrication is done using our specially manufactured 4/0 double-armed nylon sutures (Aurolab). Base plate is created by seventh and part of sixth costal cartilages, helix by eighth costal cartilage, antihelix by ninth costal cartilage, and tragus by remaining portion of seventh cartilage. Third-layer projection is done by remaining sixth costal cartilage. Once the cartilage framework is fabricated, it is placed in the subcutaneous pocket created for the new auricle and skin is closed with few tacking sutures; if the skin is not blanching and appears pale, the height of third layer is reduced or the third layer is totally removed. This decision is reviewed again at the end after applying suction to the drains.

The chest wound is closed in layers, after confirming the integrity of pleura. Intercostal block is given for postoperative pain relief. Auricular site closure is done over two suction drains, with one placed under the framework and one in scaphoid fossa, using 16-gauge cannulas and three-way connectors attached to 10 cc syringes. In case the skin over the framework is not blanching, the suction is reduced or removed and collection is removed every 2 hours.

The reconstructed site is kept exposed, with only ointment application and constant visual inspection is done to

observe the skin vascularity. Suture removal is done on the fifth postoperative day.

Second Stage: Framework Elevation

The goal of the second stage is to provide identical elevation of both ears. If the ear framework projection is more or less similar to the normal ear on frontal and posterior views, we do not insist on framework elevation as the operation has already served the purpose of their most important aesthetic need, the presence of a well-shaped ear framework, with semblance of an external auditory canal and ability to wear spectacles (►Figs. 2 and 3). If projection measured from mastoid to highest point of helix is at least 80% of normal ear, we do not insist on second stage. If it is less than 80%, we consider elevation and counsel the patient accordingly; however, the decision to undergo the second stage is left to the patient. In women, a second stage may be necessary to give a proper ear piercing, if primarily it has not been possible to completely transpose the lobule including both the layers together (►Fig. 3).

When the opposite ear is prominent and hinders symmetry, contralateral otoplasty is a solution, but in our experience, patients generally do not opt for it.

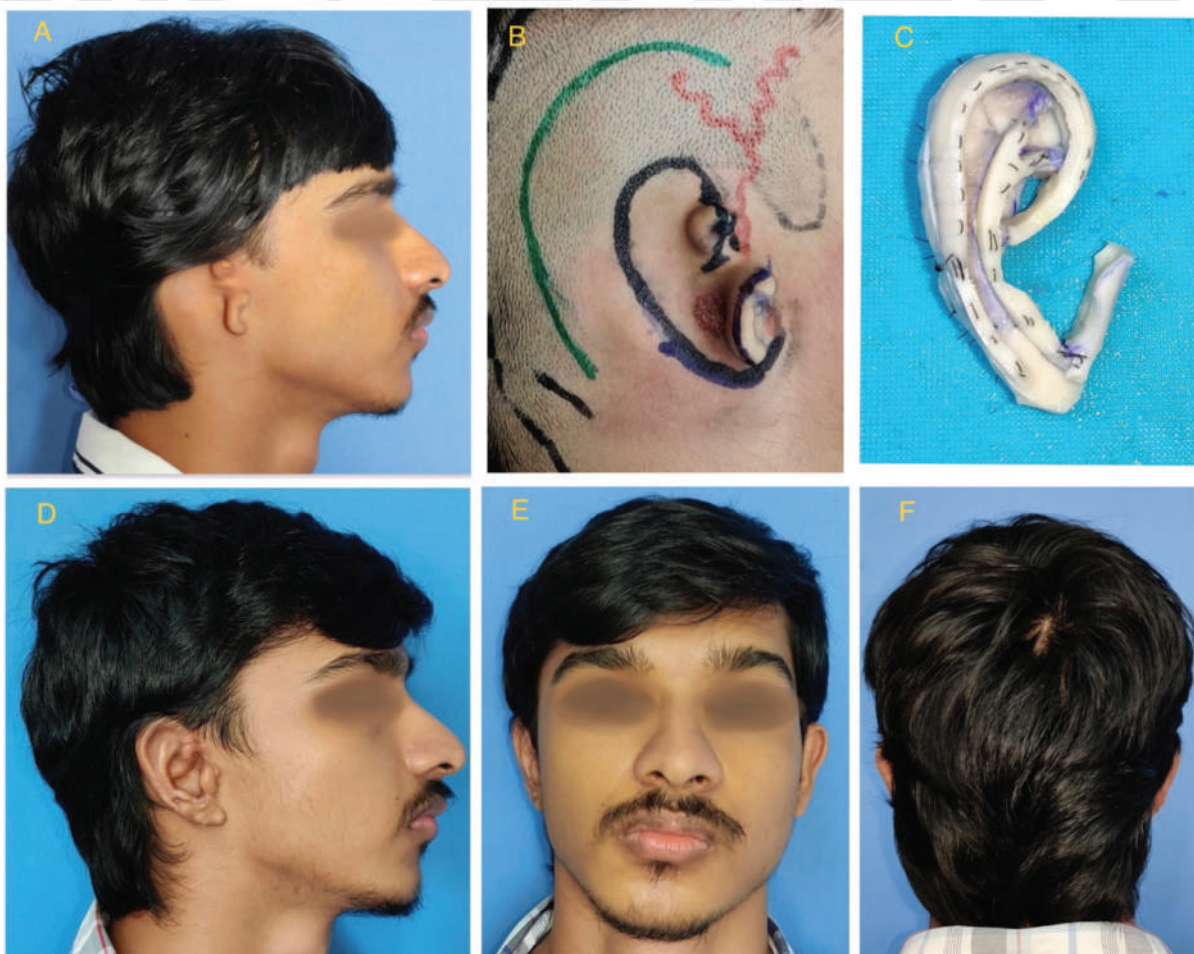

Fig. 2 A 19-year-old male with right lobule type microtia (A). Preoperative markings of subcutaneous pocket, lobule splitting incision, template, and superficial temporal artery (B) and a framework fabricated with 4-0 Nylon (C) result in the lateral, anterior, and posterior (D, E, and F) views 1.5 years post surgery.

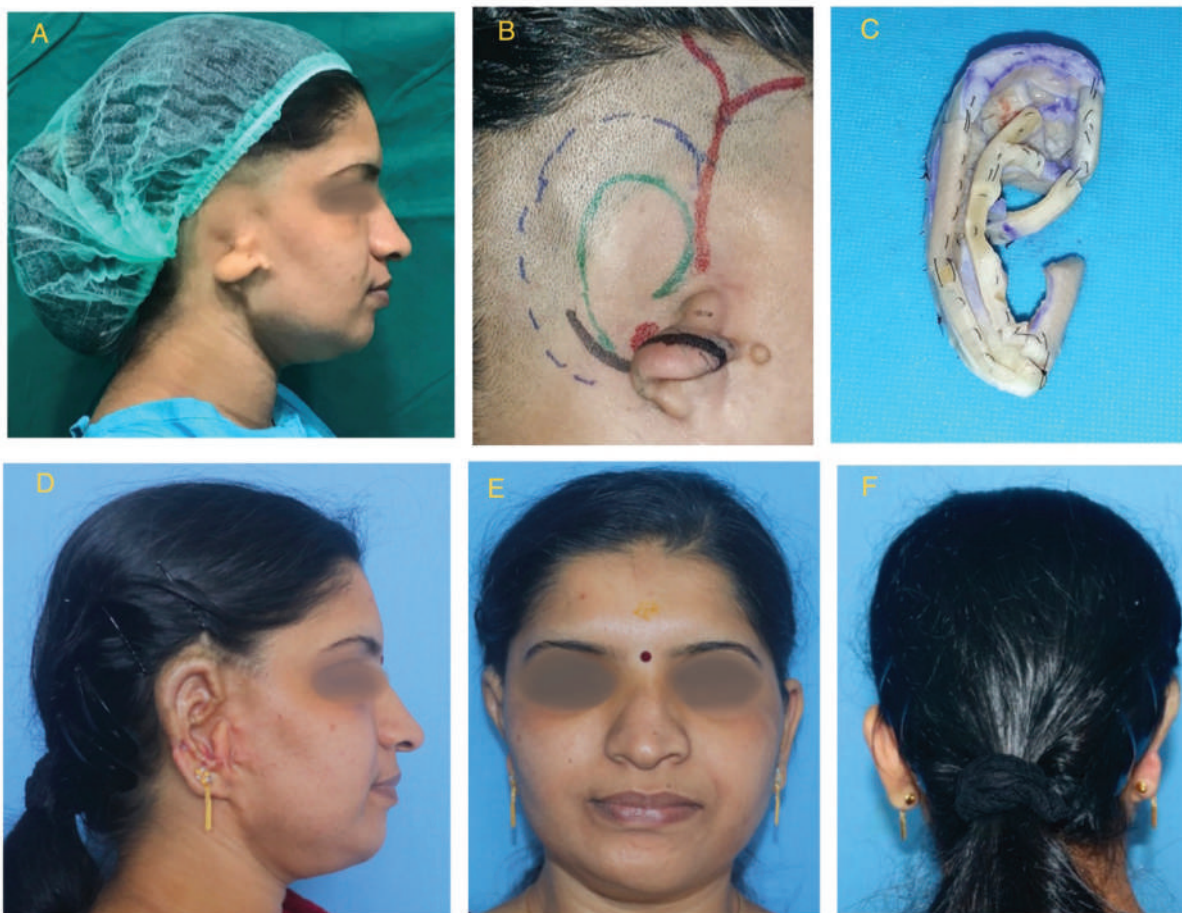

Fig. 3 A 28-year-old lady with right lobule type microtia (A). Preoperative markings of subcutaneous pocket, incision to transpose lobule, template, and superficial temporal artery (B) and a multipiece framework fabricated with 4-0 Nylon (C) result in the lateral, anterior, and posterior (D, E, and F) views 1.5 years post surgery.

If the primary framework projection is not adequate, the second stage is performed after 6 months of the primary surgery.

Framework elevation is done as per Nagata technique (►Fig. 4). Harvesting the skin graft is done from adjacent scalp with a hand-held knife or dermatome. Once graft is settled, a ring splint fabricated from silicone Foley catheter (►Fig. 5) is used for at least 6 months postoperatively to maintain the elevation and prevent the effacement of the newly formed postauricular sulcus. During this time, the patient is advised to use a soft pillow and avoid lying down on the operated side; in children a protective ear cover is used.

Results

Out of 28 patients who underwent reconstruction for microtia, 4 were secondary reconstructions and were excluded from this study. A total of 24 patients underwent primary ear reconstruction; 4 among them had bilateral reconstruction, so a total of 28 ears were reconstructed. Second stage of framework elevation was done in eight ears. All of them had a minimum follow-up of 6 months. The age group of the patients ranged from 11 to 29 years, with a mean of 17.68

years. Thirteen of them were males and 11 females. Majority of them had lobule type of microtia (21 patients), one had concha type, two had anotia, and four had atypical microtia. Associated conditions included hemifacial microsomia (four patients) and Goldenhar syndrome (two patients).

Framework fabrication in 20 ears was done by stainless steel sutures, nylon sutures were used in 6, and both (hybrid) were used in 2 ear reconstructions.

As per patient age at the time of ear reconstruction, they were divided into two groups: 11 ear reconstructions were in patients below 15 years of age and 17 were in patients 15 and above in age. The outcomes were graded as poor, fair, or good. Only 1 (9%) ear in the below 15 group was graded as good on long-term follow-up, 5 (45.5%) were graded as fair, and 5 (45.5%) as poor, whereas in the 15 and above group, 9 (53%) had good outcomes, 5 (29%) fair, and only 3 (18%) ears were graded as poor. Coming to cartilage resorption, in the below 15 category, 10 ears out of 11 showed moderate to severe resorption, whereas in the 15 and above category, 7 out of 17 showed moderate to severe resorption and 10 ears had nil to mild resorption.

Ten patients underwent secondary procedures such as skin tag excision, lobule repositioning, framework repositioning, selective augmentation/reduction, BAHA—bone

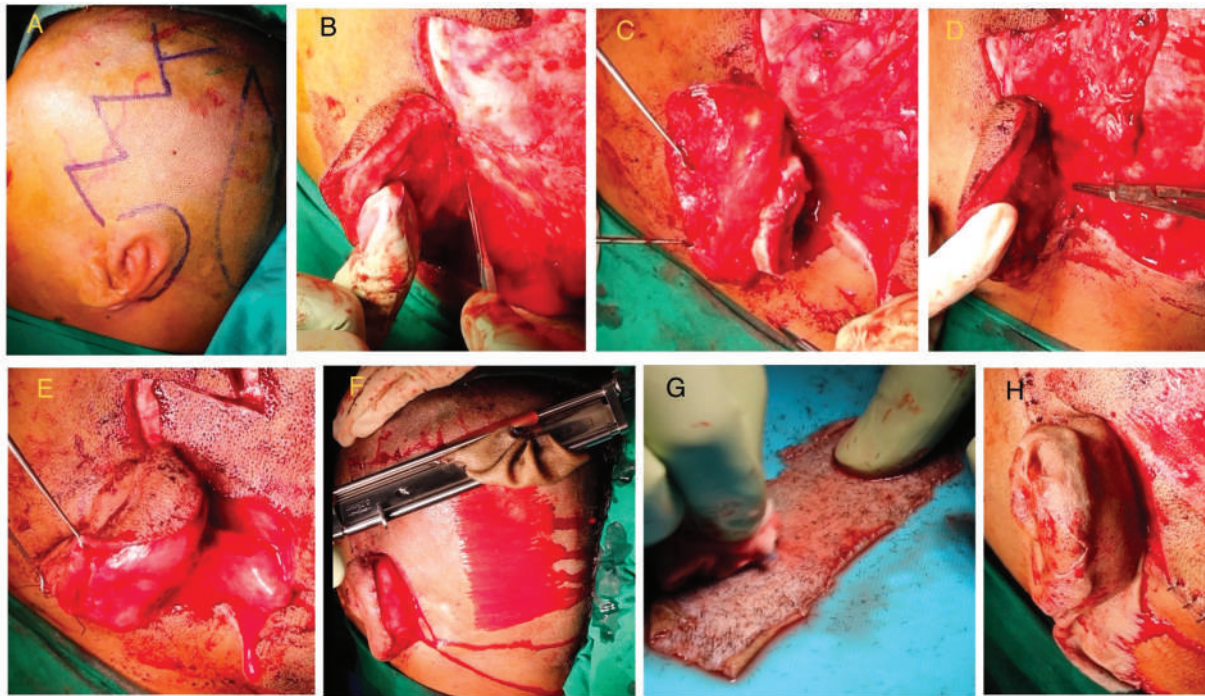


Fig. 4 Second stage: Incision planned for framework elevation and temporoparietal fascia harvest (A). Elevation of framework (B). Banked cartilage placed (C). Securing cartilage block to the framework with 3-0 PDS (D). Temporoparietal fascia flap covers the cartilage (E). Harvesting split thickness graft from adjacent scalp (F) and covering temporoparietal fascia with the skin graft (H). The hair in the skin graft is removed manually (G).

anchored hearing aid—placement, secondary suturing, and secondary reconstruction.

Details of complications are presented in ►Table 1.

Discussion

Auricular reconstruction presents a surgical challenge because of the complexity of the normal ear structure.

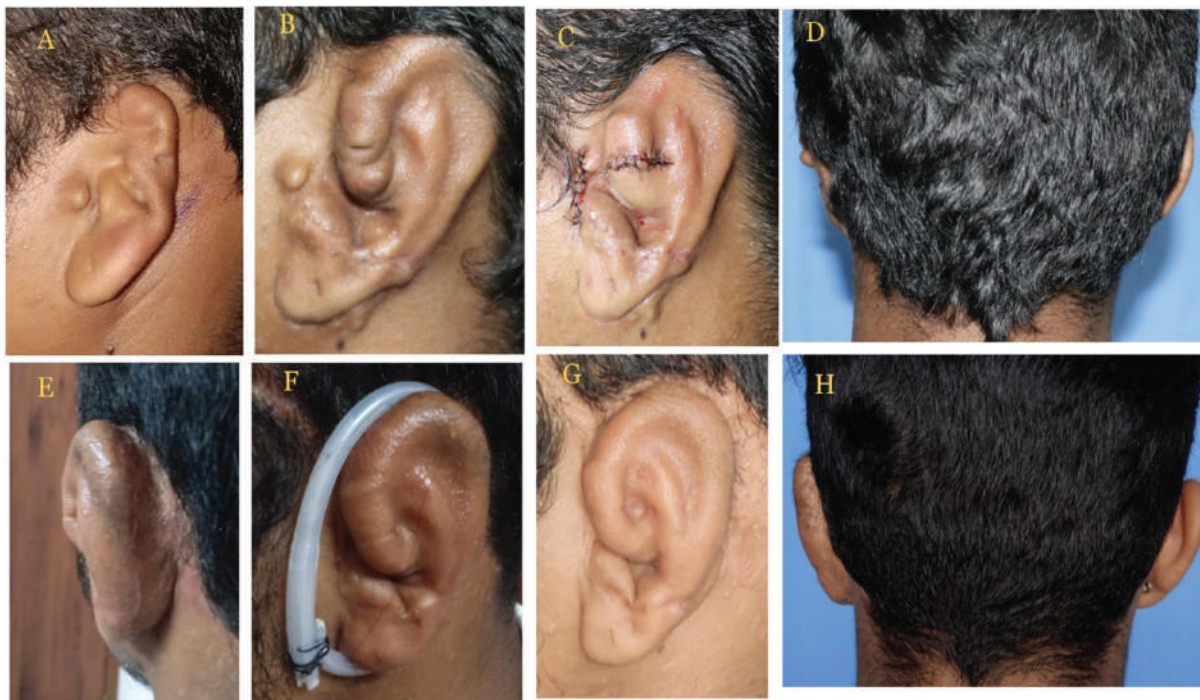

Fig. 5 An 18 year old male with left lobule type microtia (A). Result after stage 1 reconstruction (B). Secondary correction 3 months after the first stage (C). Note the inadequate projection after stage 1 (D). Result after second stage, that is, framework elevation (done 6 months after the first stage) (E). Silicone ring splint (F). Final appearance without splint (G). The final result 7.5 years post surgery, note improvement in projection (H).

Table 1 Complications

Complication			Frequency	Outcome	Remarks
Early complications	Skin vascular compromise	Major (>1 cm ²)	3	Fair (1)	Managed by temporoparietal fascia flap
				Poor (2)	Debridement + antibiotics
	Minor (<1 cm ²)	3	Good	Managed by Limberg flap/secondary suturing	
	Infection		5	Poor	Managed by debridement + antibiotics
Late complications	Cartilage resorption	Nil	3	Good	Minor skin necrosis; no resorption; settled by 4–6 months postoperatively
		Mild	8	Good	14–21 years age; no inciting factors; stabilized by 1 year postoperatively
		Moderate	9	Fair	11–28 years; 1 had wire extrusion; 5 had cartilage resorption
		Severe	8	Poor	6 had infection; 2 had multiple wire extrusions
	Wire extrusion		7	Fair (1) Poor (6)	Stainless steel sutures; multiple extrusions over 1 year; 5 had infection

Achieving an aesthetically satisfactory result depends on having a well-sculpted framework covered by a thin and vascular skin flap. Over the past 7 years, our approach toward management of microtia has evolved with respect to timing of procedure,¹² and technique and management of postoperative complications.

Age at reconstruction: Tanzer,^{5,6} Brent,⁷ and Firmin et al¹³ cite early reconstruction at 6 to 8 years of age, whereas in Nagata technique^{8–11} the ideal time is around 8 to 10 years. In our experience, the results with early reconstruction at or below 10 years have been disappointing, with a high incidence of resorption over 1 to 3 years postoperatively.¹² Resorption incidence of 0 to 63%^{14–16} is reported and is more common with Nagata-style reconstruction at 12%. In our series, of the 11 ears reconstructed at less than 15 years of age, only 1 (9%) had a good long-term outcome, whereas of the 17 ears reconstructed at or above 15 years of age, 9 (53%) had a good long-term outcome. When operated at less than 15 years of age, cartilage resorption was much more evident. When we increased the age to at or above 15 years, the results were more sustainable. To correlate with chest circumference, we performed anthropometric analysis of chest circumference in children of 10 to 18 years of age (276 girls and 335 boys) and found out that average chest circumference at or above 15 years of age in boys was 84.73 cm and in girls was 75.18 cm.

Now we prefer to initiate reconstruction at around 15 years of age and with a minimum chest circumference of 75 cm in order to obtain good quality and adequate volume of cartilage. In older patients, computed tomography of chest can guide us to harvest cartilage from the less ossified side.¹³

Framework profile: Microtia reconstruction is a balancing act between getting a good three-dimensional ear framework with adequate projection and viability of the overlying skin. A high-profile framework ensures definition and projection but it can make blood supply of the overlying skin precarious. Low-profile framework results in poor definition and defeats the purpose of this already complex reconstruc-

tion. Reducing the height of the third layer in select cases has reduced the number of patients experiencing compromise in skin vascularity.

Stainless steel wires are used by Nagata^{8–11} and Firmin et al¹³ for framework fabrication but we have seen that they have a high risk of extrusion and almost all of our previous patients had some issue with the steel wire extrusion (►Fig. 6). Wire extrusion with concomitant skin breakdown increases the chances of local infection, further increasing the chances of cartilage resorption. Therefore, now we use a specially manufactured 4/0 double-armed nylon suture with straight needles; nylon has high tensile strength and hence no problem of extrusion.

Number of stages: Single-stage ear reconstruction has been attempted earlier with good acceptance.¹⁷ Instead of a dogmatic approach, the necessity of a second stage is tailored to the individual's requirements. With an adequately high-profile framework, 10 patients (41.6%) were satisfied with the first stage and opted out of the second stage. Second stage was done mainly to further improve projection in eight patients (33.3%) whose ear profiles were not adequate (►Fig. 7).

Postoperative splint: In patients who undergo the second stage of reconstruction, we have devised a unique *ring splint* made of a silicone Foley catheter (►Fig. 5). It is easy to make in the office setting, very cheap, and reliable regarding retention and for prevention of graft contraction and effacement of sulcus over time.

Low hairline: In patients with a low hairline, removal of the hair is done preoperatively by LASER—light amplification by stimulated emission of radiation—intraoperatively by excision of the hair follicles during second stage of elevation, and even after the second stage the remnant hair follicles can be further removed by LASER (diode LASER, 810 nm; starting with optical energy of 10 J).

Skin tags: We prefer to be extremely cautious regarding the excision of excess skin that remains at the end of the first stage of operation (►Fig. 5). In our understanding, the

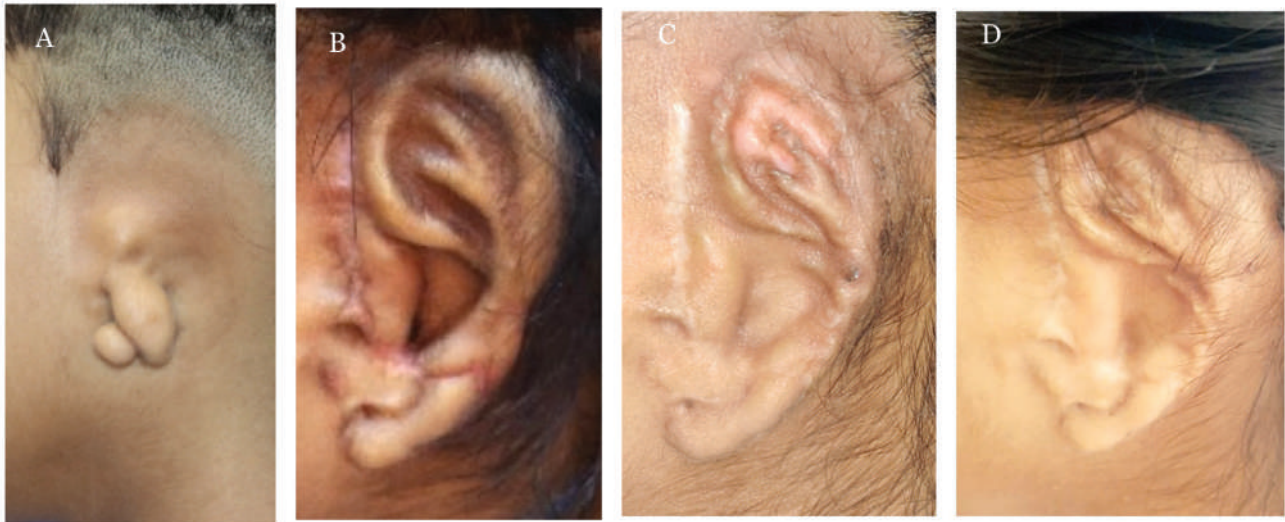

Fig. 6 A 13-year-old girl with lobule type microtia (A). Post stage 1 reconstruction; stable result for about a year (B). Late extrusion of multiple stainless steel wires (C). Resorbed cartilage after 2 years (D).

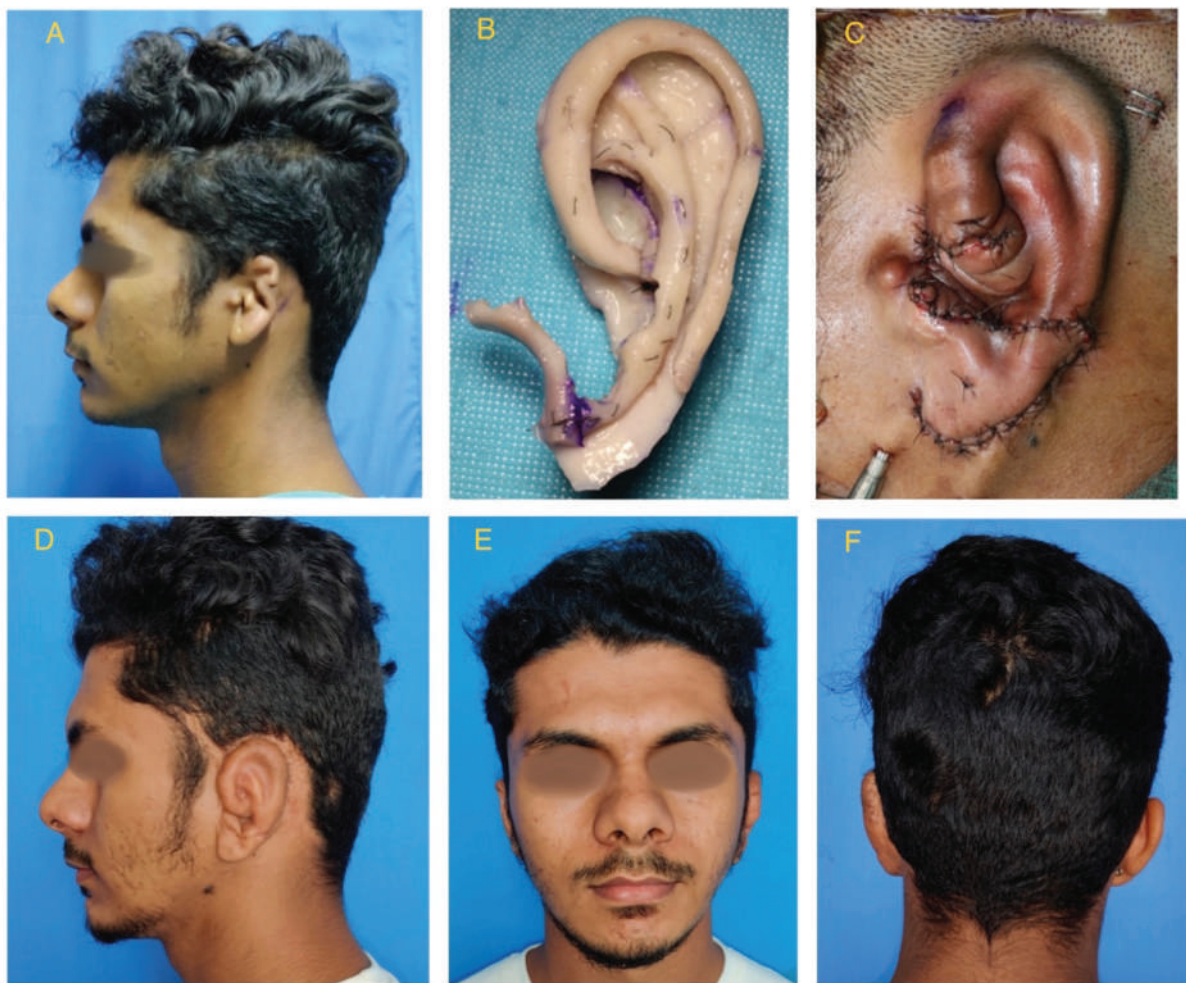

Fig. 7 An 18-year-old male with left lobule type microtia (A). Framework fabricated using both stainless steel wires and nylon sutures (B). Immediate postoperative result (C). Secondary corrections and second-stage elevation are depicted in ►Figs. 4 and 5. Result after 2.5 years after both stages of reconstruction (D, E, and F).

overzealous excision of excess skin during the first stage may lead to a compromise of blood supply and cause skin necrosis. In most cases, the removal of the excess skin is done 1 or 2 months after the first stage.

Framework creation in adults: In adults, as the cartilage is ossified and brittle, creating helix and antihelix from a single piece of cartilage is difficult. To get the right curvature, the template is placed over the cartilage and specific portions of cartilage are cut out according to the shape of the template and joined together to achieve the desired shape (► Fig. 3). As the pieces are separate, there is no deforming tensile force, and a strong and stable framework can be easily created. Great care is taken to join the pieces with precision.

Complications

In our experience, infections and wire extrusions were the significant events preceding severe cartilage resorption. These events occurred more frequently in younger patients than older ones. With age, cartilage becomes stronger; with some calcification, it becomes tough and slightly brittle. This property seems to improve the ability of the cartilage to resist the shearing forces of contracting skin pocket. The wires do not extrude if the cartilage does not resorb and skin pocket is intact. On the contrary, in younger patients the cartilage appears to be more pliable and less strong and our observation is that it resorbs over a period of time; the cartilage resorption leads to extrusion of wires, which leads to superimposed infection, further enhancing the resorption. With changes in technique and the type of suture materials used, there have been no infections or wire extrusions for cases operated in the last 3.5 years. Minimal skin necrosis is not uncommon and does not adversely affect the final outcome. In our understanding, the most important thing is to maintain the subcutaneous pedicle at the conchal region as described by Nagata.⁸⁻¹¹ It creates immediate semblance of a conchal bowl, maintains blood supply of the skin at the most precarious region, and helps in fixing the position of the framework once it is placed.

Conclusion

In our experience, delaying the first stage to 15 years or later, using double-armed nylon sutures, and avoiding third layer in select cases have helped to improve our outcomes. Second stage of reconstruction can be avoided if adequate projection is achieved in the first stage.

Conflict of Interest

None declared.

References

- 1 Sakharkar B, Vithalani L. Sandhan karma -base of modern plastic and reconstructive surgery. *Rasamruta* 2013;5:19
- 2 Potalia P, Gupta RK, Sharma VD. Sandhan karma -base of ayurveda and modern sciences -a review. *Int Res J Ayurveda Yoga* 2021;4(09):151-161
- 3 Weerda H. History of auricular reconstruction. *Adv Otorhinolaryngol* 2010;68:1-24
- 4 Madjidi A. Historic aspects of ear reconstruction. *Semin Plast Surg* 2011;25(04):247-248
- 5 Neligan PC, Yamada A, Harada T. Auricular reconstruction. In: *Plastic Surgery*. London u.a.: Elsevier Saunders; 2018
- 6 Tanzer RC. Microtia—a long-term follow-up of 44 reconstructed auricles. *Plast Reconstr Surg* 1978;61(02):161-166
- 7 Brent BD. Reconstruction of the ear. In: Neligan PC, ed. *Plastic Surgery*. 3rd ed. Philadelphia: Elsevier Saunders; 2013:187
- 8 Nagata S. Modification of the stages in total reconstruction of the auricle: Part I. Grafting the three-dimensional costal cartilage framework for lobule-type microtia. *Plast Reconstr Surg* 1994;93(02):221-230, discussion 267-268
- 9 Nagata S. Modification of the stages in total reconstruction of the auricle: Part II. Grafting the three-dimensional costal cartilage framework for concha-type microtia. *Plast Reconstr Surg* 1994;93(02):231-242, discussion 267-268
- 10 Nagata S. Modification of the stages in total reconstruction of the auricle: Part III. Grafting the three-dimensional costal cartilage framework for small concha-type microtia. *Plast Reconstr Surg* 1994;93(02):243-253, discussion 267-268
- 11 Nagata S. Auricular reconstruction: congenital auricular defects—microtia. In: Guyuron B, Eriksson E, Persing J, eds. *Plastic Surgery: Indications and Practice*. Philadelphia: Saunders Elsevier; 2008
- 12 Sharma M, Dudipala RR, Mathew J, et al. Objective analysis of microtia reconstruction in Indian patients and modifications in management protocol. *Indian J Plast Surg* 2015;48(02):144-152
- 13 Firmin F, Dusseldorp J, Marchac A. *Auricular Reconstruction*. New York: Thieme; 2017
- 14 Ronde EM, Esposito M, Lin Y, van Etten-Jamaludin FS, Bulstrode NW, Breugem CC. Long-term aesthetics, patient-reported outcomes, and auricular sensitivity after microtia reconstruction: a systematic review. *J Plast Reconstr Aesthet Surg* 2021;74(12):3213-3234
- 15 Ronde EM, Esposito M, Lin Y, van Etten-Jamaludin FS, Bulstrode NW, Breugem CC. Long-term complications of microtia reconstruction: a systematic review. *J Plast Reconstr Aesthet Surg* 2021;74(12):3235-3250
- 16 Kim A, Park HY, Lee H, Oh KS. Risk factors for delayed resorption of costal cartilage framework following microtia reconstruction. *Facial Plast Surg Aesthet Med* 2020;22(06):456-463
- 17 Kasrai L, Snyder-Warwick AK, Fisher DM. Single-stage autologous ear reconstruction for microtia. *Plast Reconstr Surg* 2014;133(03):652-662